

✓ 1.5  
**‘Hemorrhagic Disease of New Born’ (HDN) as a cause for sudden infant deaths**

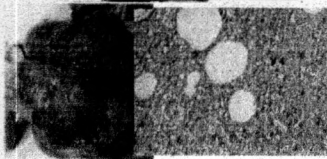
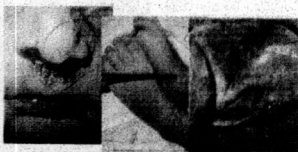Gunethilake KMTB<sup>1</sup>, Vidanapathirana M<sup>2</sup>

<sup>1</sup>Consultant Judicial Medical Officer, Provincial General Hospital, Ratnapura, Senior Lecturer, Department of Forensic Medicine, Faculty of Medical Sciences, University of Sri Jayawardēnepura

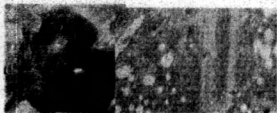Corresponding author: mudithavidana@sjp.ac.lk

**Introduction:** Haemorrhagic disease of new-born (HDN) may easily be misinterpreted as Sudden infant death syndrome (SIDS). HDN is now considered as vitamin K deficiency related bleeding. They are apparently healthy and dying during sleep can be traumatizing to the family. It further complicates, when it is found a treatable condition. Allegation of child abuse also can be levelled against parents due to unexpected bleeding. By making loose diagnosis such as “SIDS, overlay, or undetermined”, without considering all the possibilities, may lead to risk of putting other siblings at risk of dying of treatable conditions. The three cases discussed below, shows the value of performing histopathology and make objective diagnosis of HDN.

**Case report:** Unexplained sudden deaths of three apparently healthy neonates occurred during sleep on 3<sup>rd</sup>, 4<sup>th</sup> and 5<sup>th</sup> day after birth respectively. Antenatal and post natal histories were unremarkable. Prophylactic vitamin K had not been given prior to discharge. At autopsies, evidence of bleeding tendency was found and there were bleeding in to lungs. Cut sections appeared dark and histopathology revealed massive pulmonary haemorrhages.



**Case 1-**Fig. 1, 2, 3, 4 & 5 show bleeding at nose, puncture sites, scalp and lung



**Case 2-** Fig.6.and 7 show lung haemorrhages



**Case 3-**Fig.8, 9, 10, 11 and 12 show bleeding at nose, umbilicus, scalp and lungs

**Discussion**

According to external and autopsy findings, above three cases should have been fallen into the category of SIDS.

If not for the two important findings, the presence of massive lung haemorrhages in histopathology and the absence of prophylactic Vitamin K injection after birth, the postmortem diagnosis would have been “undetermined” or SIDS, creating parental anxiety. Therefore, in this case, ultimately, SIDS was excluded and the diagnosis of HDN was made.

New born infants are potentially at risk of developing hemorrhage due to deficiency of vitaminK. Therefore, they should be provided exogenous vitamin K through IM injections prophylactically [1]. This is a standard practice in Sri Lanka and failure to give vitamin K prior to discharge of these three children may amount to medical malpractice and negligence.

**Conclusions**

The main difference between HDN and SIDS may only be the histological diagnosis of significant lung haemorrhages in infants who had not been given prophylactic vitamin K. This reiterates the importance of performing histopathology and make objective diagnosis of HDN and prevent HDN deaths in the future.

**References**

1. Victora C. Vitamin K deficiency and haemorrhagic disease of the newborn: a public health problem in less developed countries. UNICEF staff working papers. Feb 1997. Available at [http://www.unicef.org/spanish/evaldatabase/files/Global\\_1997\\_Vitamin\\_K\\_retrieved\\_on\\_24.01.2016](http://www.unicef.org/spanish/evaldatabase/files/Global_1997_Vitamin_K_retrieved_on_24.01.2016)