

317,

PP 4

A fabricated scene of suicide

Amararatne RRG¹, Jayasundara S², Perera C², Vidanapathirana M³

¹Consultant JMO, ²MO-Medico- Legal, Base Hospital, Puttalam, ³Senior Lecturer, Department of Forensic Medicine, Faculty of Medical Sciences, University of Sri Jayewardenepura

Corresponding author: mudithavidana@sjp.ac.lk

Introduction

Suicidal and homicidal firearm deaths are not uncommon. In some instances, attempts are made by the criminals to conceal homicides as suicidal deaths. The case under discussion highlights the contribution of the forensic pathologist in the ascertainment of the manner in a firearm death.

Case report

The deceased was a poacher and his dead body was found in a cashew land with his shotgun lying over him (Fig 1). The shirt had a roughly circular loss of fabric with burnt and blackened margin, and a faint muzzle mark (Fig. 2). Beneath that, a circular shaped, perforated laceration, 2 cm diameter with a 0.5cm circumscribed muzzle imprint on front of the left upper chest (Fig 3). Shelving at the upper margin. Chest X-ray showed the downward pellet distribution (Fig 4). Cause of death was chest injuries due to pellets discharged from a smooth bore weapon. Upper arm reach was 65cm (25 inches) (Fig.5) and the muzzle to the trigger length was 79cm (31 inches) (Fig. 6).



Fig. 1. Body at the scene



Fig. 2. Entry on shirt




Fig. 3. Entry on body

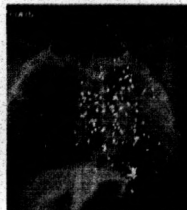

Fig. 4. Downward distribution




Fig. 5. Arm reach (25")



Figure 6. Muzzle to trigger length (31")

Discussion: Presence of muzzle imprint in shirt and around the entry, it was confirmed that the range of fire is contact. Contact or close range injuries involving the head or thorax result in instantaneous or rapid death [1]. Therefore, in this case, an instantaneous or rapid death is expected.

Victims of suicides usually pull the clothes aside to bare the skin before shooting themselves [2]. But in this case, the clothes seem to be not moved at all. It aroused the suspicion as to the manner of death. Usually, in suicides, triggering is done by feet and the weapon is kept close to the body and the direction of the fire is upwards. Direction of shelving and pellet distribution confirmed that the direction was downwards. The selection of an elective site and the contact range, suggest suicide, but the downward direction of fire was inaccessible without improvisation and is unexpected in suicide. Further, arm reach 65cm (25 inches) was much shorter than the length from the muzzle to the trigger 79cm (31 inches). An improvised apparatus was not found at the scene for triggering. Therefore, self-infliction is impossible.

Conclusion: It was found to be a fabricated suicide scene and the manner of death was ascertained as homicide. This reiterates that the postmortem investigations of the firearm deaths should be performed or conducted under direct supervision of forensic specialist to deliver justice.

References

1. Werner US and Daniel JS. Sharp force injuries in Spits and Fisher's Medico-legal investigation of death, 4th ed. Springfield, IL: Charles C Thomas Publishers, 2006, pp 532-606.
2. Rao D. Firearm injuries in Forensic pathology, e-book. <http://www.forensicpathologyonline.com/E-Book/firearm-injuries>