

145

328

ISSN: 2229-516X




Vol 6 · Issue 4 · Oct-Dec 2016

# International Journal of Applied & Basic Medical Research


Official Publication of Basic Medical Scientists Association

[www.ijabmr.org](http://www.ijabmr.org)

Medknow

 Wolters Kluwer

**PubMed**  
Indexed



## Sudden death of a middle-aged man with an artificial vagina *in situ*

Muditha Vidanapathirana, Rohan P Ruwanpura<sup>1</sup>, Sriyantha RRG Amaratne<sup>2</sup>

Department of Forensic Medicine, Faculty of Medical Sciences, University of Sri Jayewardenepura, Nugegoda, <sup>1</sup>Department of Forensic Medicine, Teaching Hospital, Karapitiya, Galle, <sup>2</sup>Department of Forensic Medicine, Institute of Legal Medicine and Toxicology, Colombo, Sri Lanka

### ABSTRACT

Artificial vaginas are designed to imitate the female sex organ. This is the first reported case in the forensic literature of a man being pronounced dead with an artificial vagina *in situ*. A middle-aged man was found unconscious in a bathroom when the door was forced open and was pronounced dead on admission. Autopsy revealed that the penis was inside an artificial vagina. There were no injuries, but there were left ventricular hypertrophy, myocardial fibrosis, and narrow coronaries. The cause of death was ascertained as ischemic heart disease due to coronary atherosclerosis and the comments included were no evidence of violence, and ischemic heart disease could have been precipitated due to abnormal sexual activity. If removal of artificial vagina was done before the admission, this circumstance could not have ascertained. Removal of such devices before admission to hospitals could be the reason why such incidents do not come to light.

**Key words:** Artificial vagina, *in situ*, sudden death

**Submission:** 07-09-2015 **Accepted:** 25-06-2016

### INTRODUCTION

Artificial vaginas are designed to imitate the female sex organ and to achieve this, they are made out of a soft material, lubricated, and sometimes heated.<sup>[1]</sup> Further, the artificial vaginas are made for medical research purposes, animal breeding, or as a sex toy for erotic stimulation.<sup>[1]</sup> They can be internal or external artificial vaginas. The internal artificial vagina (IAV) usually permits semen sampling, as well as mating ability evaluation among animals.<sup>[2]</sup> IAVs of male-to-female transsexuals' are constructed by penile skin invagination.<sup>[3]</sup> In females with vaginal agenesis, an artificial vagina is surgically made at the site of the absent vagina.<sup>[4]</sup>


Address for correspondence: Dr. Muditha Vidanapathirana, Department of Forensic Medicine, Faculty of Medical Sciences, University of Sri Jayewardenepura, Nugegoda, Sri Lanka. E-mail: mudithavidana@sjp.ac.lk

An artificial vagina for the purposes of human sexual stimulation is essentially an aid to human masturbation, and it is designed to simulate the sensation of sexual intercourse. It will often have moving parts such as vibrators that increase stimulation.<sup>[5]</sup>

In this instance, a middle-aged male was found dead in his bathroom with an artificial vagina *in situ*. This is the first such reported case in the forensic literature.

### CASE REPORT

Wife of the deceased heard that her 46-year-old husband was shouting in the bathroom around 6 pm. The door of the bathroom was forced open and the deceased was found lying unconscious. He was clad in sarong and bare-chested. There was no evidence of any pornographic material in the

Access this article online	
Quick Response Code:	Website: www.ijabmr.org
	DOI: 10.4103/2229-516X.192592

This is an open access article distributed under the terms of the Creative Commons Attribution-NonCommercial-ShareAlike 3.0 License, which allows others to remix, tweak, and build upon the work non-commercially, as long as the author is credited and the new creations are licensed under the identical terms.

For reprints contact: reprints@medknow.com

**How to cite this article:** Vidanapathirana M, Ruwanpura RP, Amaratne SR. Sudden death of a middle-aged man with an artificial vagina *in situ*. Int J App Basic Med Res 2016;6:287-9.

Vidanapathirana, *et al.*: Deceased with an artificial vagina *in situ*

bathroom. He had been brought to a tertiary care hospital of Sri Lanka within half an hour, but was pronounced dead on admission.

He was a carpenter by profession and had no history of any significant illness including diabetes mellitus, epilepsy, or on long-term treatment, but was a chronic smoker.

Autopsy revealed that he was an average-built and moderately-nourished person. A whitish froth was found over the nostrils. There was no external evidence of diseases or injuries. After removing the sarong, it was evident that the penis was inside an artificial sex toy, an *in situ* artificial vagina [Figures 1 and 2]. On inspection of the artificial vagina, evidence of ejaculation was not apparent, and the laboratory report for seminal or sperms was negative. There was no history of previous similar practices, and the wife was not aware about this apparatus.

Lungs showed congestion, and the airways were filled with froth. Complicated atheromatous plaques were found mainly in the infrarenal part of the aorta.

The heart was 350 g in weight, and the lumen of the left anterior descending artery was pinpoint [Figure 3], the right coronary and left circumflex branches showed more than 75% narrowing. The left ventricle was hypertrophied, and fibrotic areas were found in the anterior, lateral, and posterior walls. Other organs including brain were unremarkable. Musculoskeletal dissection revealed no injuries. Blood was negative for alcohol and common poisons. Histopathology revealed atheroma in coronaries and fibrosis in the myocardium. Lungs showed pulmonary edema, and other organs including kidneys and brain were unremarkable.

The cause of death was ischemic heart disease due to coronary artery atherosclerosis. In addition, the following comments were made. (a) No evidence of violence, (b) toxicology tests were negative, (c) histopathology re-confirmed the cause of death, and (d) ischemic heart disease could have been precipitated due to indulging abnormal sexual activity using an artificial vagina.

## DISCUSSION

Usually, the artificial vagina for human sexual stimulation has a realistic or close to realistic appearance with a sleeve, where the penis can be inserted.<sup>[5]</sup> However, in this case, such sleeve was not found and did not simulate the real appearance of female vulva.

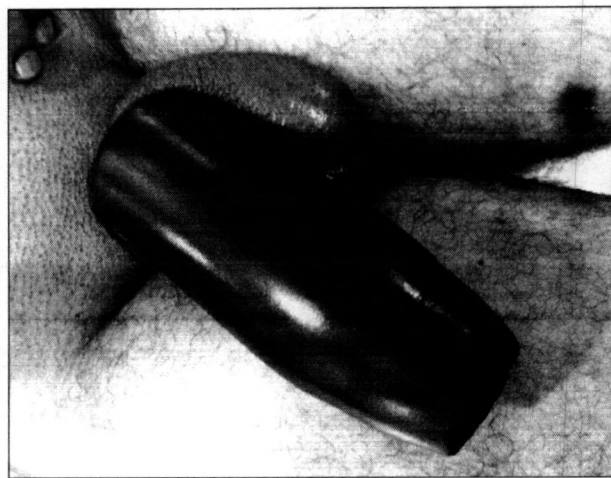


Figure 1: *In situ* artificial vagina



Figure 2: The artificial vagina after removal

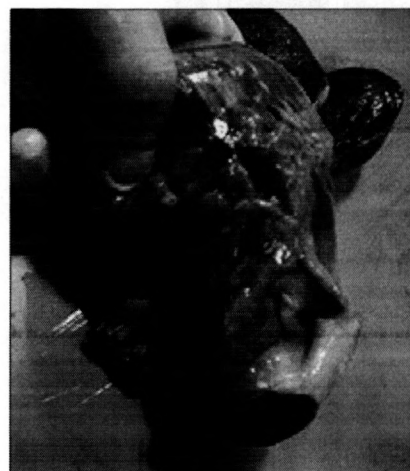

Figure 3: The lumen of the anterior descending artery was pinpoint

Ischemic heart disease is the most common cause of sudden death, and the coronary atheroma is the most common contributor.<sup>[6]</sup> Pin-hole lumen was due to concentric narrowing<sup>[7]</sup> of the coronary arteries due to atheroma. The

left ventricular hypertrophy could have been due to a condition such as hypertension that may have been left unknown due to masking by another nonsignificant illness, ignorance, misinterpretation, or rationalization. In the presence of fibrotic areas with all the three coronaries that were narrow, the autopsy findings were compatible with the cause of death; ischemic heart disease due to coronary artery atheroma. Hypertrophied left ventricle was a contributory factor.

Ischemic heart disease precipitates due to relative ischemia and due to transient risk factors such as exertion, psychological stress, heavy meal, and sexual activities.<sup>[8]</sup> In this circumstance, the presence of an *in situ* artificial vagina suggests that the deceased would have been practicing an abnormal sexual activity, and it could have caused relative ischemia and the death of this person.

## CONCLUSIONS

Since this special device was left hidden under the sarong, it had not been removed by the relatives before the admission. Had it been removed before admission, this circumstance could not be ascertained. This is the first reported case in the forensic literature of a man being pronounced dead with an artificial vagina *in situ*. Removal of such devices before admission to hospitals could be the reason why such incidents do not come to light.

## Acknowledgment

We like to thank the next of kin of the deceased for providing the details of the incident and the official photographer for obtaining photographs.

## Financial support and sponsorship

Nil.

## Conflicts of interest

There are no conflicts of interest.

## REFERENCES

1. Kobori Y, Ryo S, Yoshio A, Hiroshi Y, Shigehiro S, Gaku A, et al. Rehabilitation for ejaculatory dysfunction with using a masturbator. *Japanese Journal of Impotence Research* 2009;24:355-7.
2. Cruz FB, Lohn L, Marinho LS, Mezzalana JC, Neto SG, Martins LT, et al. Internal artificial vagina (IAV) to assess breeding behavior of young *Bos taurus* and *Bos indicus* bulls. *Anim Reprod Sci* 2011;126:157-61.
3. Hausteil UF. Pruritus of the artificial vagina of a transsexual patient caused by gonococcal infection. *Hautarzt* 1995;46:858-9.
4. Grys E, Friebe Z. Evaluation of the influence of some factors for determining the effect of surgical creation of an artificial vagina. *Ginekol Pol* 1994;65:307-13.
5. Artificial Vagina. Available from: [https://www.en.wikipedia.org/wiki/Artificial\\_vagina](https://www.en.wikipedia.org/wiki/Artificial_vagina). [Last accessed on 2016 May 14].
6. Zipes DP, Wellens HJ. Sudden cardiac death. *Circulation* 1998;98:2334-51.
7. Knight B. *Forensic Pathology*. 2<sup>nd</sup> ed. London: Arnold; 1996. p. 488-9.
8. Spitz WU, Spitz DJ. *Medico-legal Investigation of Death*. 4<sup>th</sup> ed. Illinois, USA: Charles C Thomas; 2006. p. 307.