

Proceedings and Abstracts



College of Forensic Pathologists of Sri Lanka

14th Annual Academic Sessions

Bandaranaike Memorial International Conference Hall

Buddhaloka Mawatha

Colombo 07

4th & 5th of March 2016

PP 24

The role of the forensic pathologist in the clinical management of victims of firearm injuries- a case elaboration

Raveendran S¹ Hulathduwa SR²

¹DLM Trainee, ²Senior Lecturer

Department of Forensic Medicine, Faculty of Medical Sciences, University of Sri Jayawardenapura

Introduction

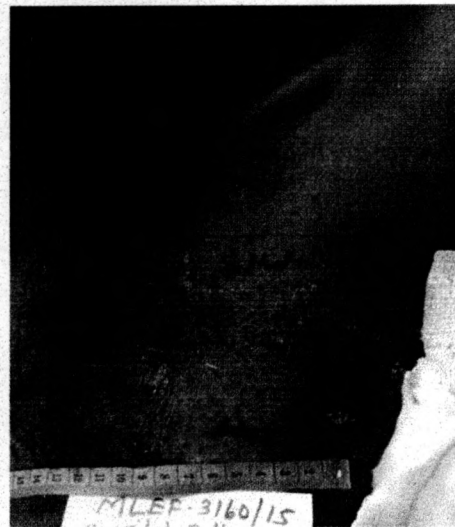Firearm injuries are commonly encountered in criminal assaults. Forensic pathologist not only plays a vital role in solving the medico-legal issues but also in the clinical management of the victim.

Case report

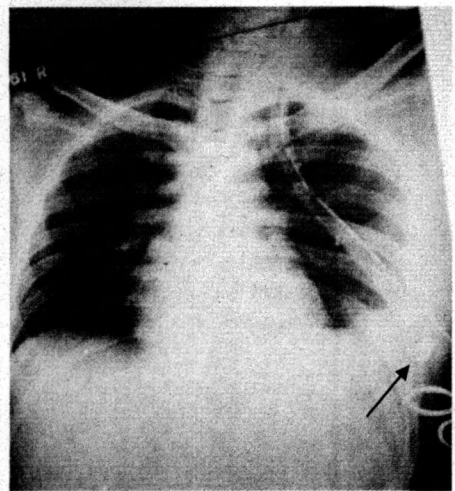
A 31 year old man was admitted to the accident service unit with multiple cut injuries. He alleged that he was assaulted with a heavy sharp weapon and also shot with a firearm resembling a revolver. Though he saw the weapon and heard the noise, he was not certain about the position of the entry wound on his own body. On admission he was in severe pain with pallor and dyspnoea. His blood pressure was 100/70 mmHg. An inter-costal drainage tube was inserted in to the left chest which drained 600 ml of blood in the first hour. All cut injuries were sutured. Four pints of blood were transfused. FAST scan was normal. The initial chest x-ray failed to detect any foreign body.

The medico-legal examination revealed tattooing around the sutured chest wound indicating it to be the entry of the projectile. The absence of an exit wound suggested the existence of the projectile within the body. Upon the request of the JMO, serial x-

rays were taken revealing the presence of a bullet at the inferior angle of the left scapula which was later removed by the surgeon.



1. Entry wound with tattooing



2. Chest X ray reveals bullet

Conclusion

This case elaborates the contribution of the JMO towards the clinical management of victims of firearm injuries. It also highlights the need of repeat serial X-rays to detect embedded foreign bodies.