

20  
2

## Double Murder Following Intoxication with Sedative Drugs

2016



Vidanapathirana M<sup>1\*</sup>, Gunethilake KMTB<sup>2</sup>

<sup>1</sup> Department of Forensic Medicine, Faculty of Medical Sciences, University of Sri Jayewardenepura, Sri Lanka

<sup>2</sup> Office of the JMO, Teaching Hospital, Baticaloa, Sri Lanka

### ARTICLE INFO

*Article Type:*  
Case Report

*Article History:*  
Received: 22 Jan 2015  
Revised: -  
Accepted: 3 Feb 2015

*Keywords:*  
Sedative drugs  
Double murder  
Cut throat

### ABSTRACT

**Background:** Sedative drugs are important in many ways in medicolegal practice. They are used to subdue or alter the mind of a victim and also such drugs themselves can cause death. These drugs are used in robberies as well as in murder cases.

**Case Report:** Two averagely built healthy parents were found dead on bed with deep cut injuries to neck, with minimal evidence of volitional activities and defense injuries. An involvement of a poison was suspected. The elder daughter had felt a bitter taste of the dinner and kept it in the refrigerator at that night. The dinner was sent for toxicological investigations. Causes of deaths were cut injuries to neck. At the same time, the investigators found out that the younger daughter had mixed diazepam to dinner and her boyfriend and 4 others killed the parents. A film they had watched had influenced them to initiate this incident.

**Conclusion:** Two well-built conscious adult victims in sober state should have received at least few defense injuries or leave evidence of volitional activities. In such circumstances, intoxication with drugs or incapacitated with other means should be considered by the forensic pathologist.

Copyright©2015 Forensic Medicine and Toxicology Department. All rights reserved.

► *Implication for health policy/practice/research/medical education:* Double Murder Following Intoxication with Sedative Drugs

► *Please cite this paper as:* Vidanapathirana M, Gunethilake KMTB. Double Murder Following Intoxication with Sedative Drugs. International Journal of Medical Toxicology and Forensic Medicine. 2015; 5(3): 168-70.

### 1. Introduction:

Sedative drugs are important in many ways in medicolegal practice. They are used to subdue or alter the mind of a victim and also such drugs themselves can cause death. These drugs are used in robberies as well as in murder cases.

### 2. Case Report:

Two averagely built healthy parents were found dead on bed with deep cut injuries to neck, with minimal evidence of volitional activities at the scene and defense injuries. Therefore, an involvement of a poison was suspected. The elder daughter (16 years) had felt a bitter taste of the dinner and kept it in the refrigerator at that night. The dinner was sent for toxicological investigations.

Mother had a deep cut in the neck (Fig. 1) and 3 deep cuts on the face. Father had a deep cut throat associated with 2 superficial cuts simulating 'trial cuts' (Fig.2), a deep cut

*Corresponding author:* Vidanapathirana M,  
Department of Forensic Medicine, Faculty of Medical Sciences, University of Sri Jayewardenepura, Sri Lanka.  
E-mail: mudithavidana@gmail.com

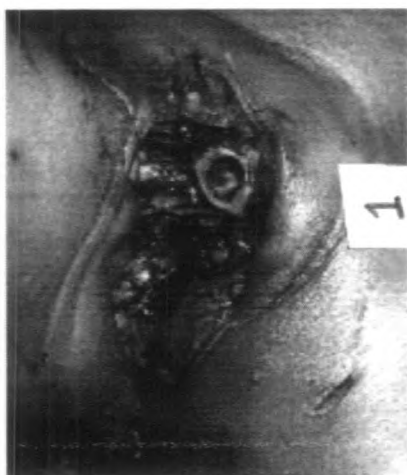


Fig. 1. Deep cut throat of mother.

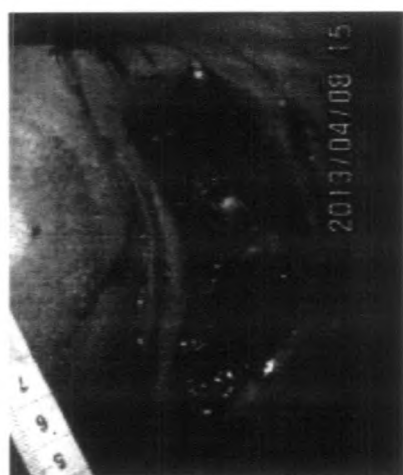

Fig. 2. Deep cut throat of father.



Fig. 3. Defense injury of father.

on face and a deep defense cut on the left forearm (Fig. 3). Blood samples were sent for toxicological analysis. Causes of deaths were cut injuries to the neck.

At the same time, the investigators found that the younger daughter (14 years) had

mixed diazepam to the dinner (fish curry) and her boyfriend and 4 others killed the parents. A film they had watched had influenced them to initiate this incident. Awaiting toxicology results of sample of dinner and blood samples of both parents.

### 3. Discussion:

Cut throats could be of homicidal, suicidal or accidental (1). Though cuts similar to 'trial' cuts were found in the neck of father, 'homicide followed by suicide' was excluded on the types and locations of the wounds and the findings of the crime scene investigation. According to the circumstances, an honor killing by cut throat (1) was excluded and multiple homicides were suspected.

Serial killers and mass murderers operate individually rather than gangs (2). Gang homicides result from drug trade/abuse or with other crimes and usually with firearms (3). In this case, though sharp forces were used, affiliations to drug trade or abuse were considered.

Substance abuse is a root cause of homicidal cut throat violence (4). Awareness and access to sedative drugs suggests possibility of substance abuse of perpetrators. Prevailed violent culture may have been potentiated by environmental influences such as violent films too.

The sedative drugs are being misused. Sometimes they are used as recreational drugs due to the effects such as euphoria and hallucination, and can cause accidental deaths due to over intoxication (5). Due to their free availability, sedatives are often used to commit suicide (6).

Though the victims were average built and well-nourished adults, the scene visit revealed minimal volitional activities. Autopsy revealed few defense injuries and no evidence of incapacitation by injuries such as head injuries. History and the criminal investigations found that the victims were incapacitated with diazepam, a sedative drug. Sample of dinner was submitted to the government analyst for analysis of sedatives and results are waiting.

Doses of sedatives such as benzodiazepines, provide a peaceful effect with low doses, relieve anxiety with moderate doses and when used as a hypnotic to induce sleep, tend to be higher doses than to relieve anxiety (7).

Sedatives such as gamma hydroxy butyrate (GHB), flunitrazepam (Rohypnol), temazepam and midazolam (8) have been reported for their use as date rape drugs and being administered to unsuspecting patrons in bars or guests at parties to reduce the intended victims' defenses. These drugs are also used for robbing (8).

In some instances, criminals themselves take sedatives such as rohypnol before they commit crimes, as the loss of inhibitions from the drug may increase their confidence to commit the offence, and the amnesia produced by the drug makes it difficult for police to interrogate them if they are caught (9).

#### 4. Conclusion:

Two well-built conscious adult victims in sober state are expected to receive at least few defense injuries or to leave evidence of volitional activities while being killed. In the absence of such findings, intoxication with drugs or incapacitated with other means should be considered by the forensic pathologist.

#### Acknowledgments

No Acknowledgment

#### References

1. Ozdemir B, Celbis O, Kaya A. Cut throat injuries and honor killings: review of 15 cases in eastern Turkey. *Journal of Forensic and Legal Medicine*. 2013;20(4):198-203
2. Eckert WG. The Whitechapel murders: the case of Jack the Ripper. *The American Journal of Forensic Medicine and Pathology*. 1981;2(1):53-60.
3. Centers for Disease Control and Prevention (CDC). Gang homicides-five U.S. cities, 2003-2008. *MMWR Morbidity and mortality Weekly Report*. 2012;61(3):46-51.
4. Gilyoma JM, Hauli KA, Chalya PL. Cut throat injuries at a university teaching hospital in northwestern Tanzania: a review of 98 cases. *BMC Emergency Medicine*. 2014;14:1
5. Han E, Jung S, Baek S, Lee S, Chung H. Deaths from recreational use of propofol in Korea. *Forensic Science International*. 2013; 233(1-3):333-7.
6. Zilker T. Acute intoxication in adults - what you should know. *Deutsch Medizinische Wochenschrift*. 2014;139(1-2):31-46.
7. Montenegro M, Veiga H, Deslandes A. Neuromodulatory effects of caffeine and bromazepam on visual event-related potential (P300): a comparative study. *Arquivos de Neuro-psiquiatria*. 2005;63(2B):410-5.
8. Negrusz A, Gaensslen RE. Analytical developments in toxicological investigation of drug-facilitated sexual assault. *Analytical and bioanalytical chemistry*. 2003;376(8):1192-7.
9. Tony T. Rape drug' used to rob thousands. *The Observer*. (19 December 2004) <http://www.topp-stopppa.co.uk/information-and-statistics/drug-robbery.html> (Accessed 15.02.2014).