

1
19 ✓

Medico-Legal Significance of 'Self-Embedding of Foreign Bodies'

Vidanapathirana M^{1*}, Tikiri Bandara Gunathilake KM²

¹ Department of Forensic Medicine, Faculty of Medical Sciences, University of Sri Jayewardenepura, Sri Lanka

² Office of the JMO, Teaching Hospital, Baticaloa, Sri Lanka

ARTICLE INFO

Article Type:
Letter to the Editor

Article History:
Received: 10 Nov 2014
Revised: -
Accepted: 14 Nov 2014

Keywords:
Self-Embedding of needles
Munchausen syndrome
Torture

ABSTRACT

Self-embedding is a form of self-injury where foreign objects are inserted underneath the skin. Though it is reported in scientific literature, it is not being reported in forensic literature.

In the year 2010, a housemaid returned from Saudi Arabia with 24 nails and needles in her body. After arrival, she had not informed that she had been tortured by the employer.

In the year 2013, another Sri Lankan housemaid from Middle East admitted to hospital with needles in her body alleged that needles being inserted by her master. X-rays showed 4 needles in her face and limbs, placed parallel to the skin surface. She would have self-embedded these needles in a way to escape from employer.

There are cases of self-inflicted injuries in people with Munchausen syndrome, where people simulate trauma or illness in order to draw attention.

In conclusion, 'the medico-legal significance of self-embedding of foreign objects' is a new concept where the forensic physician has to exclude 'torture' by a third party before ascertaining the concept of self-harm. Multiple foreign objects, found parallel to body surface, at accessible sites and accessible directions to push foreign bodies between the thumb and index finger favors self-embedding.

Copyright©2015 Forensic Medicine and Toxicology Department. All rights reserved.

► *Implication for health policy/practice/research/medical education:* Medico-Legal Significance of 'Self-Embedding of Foreign Bodies'

► *Please cite this paper as:* Vidanapathirana M, Gunethilake KMTB. *Medico-Legal Significance of 'Self-Embedding of Foreign Bodies'. International Journal of Medical Toxicology and Forensic Medicine.* 2015; 5(3): 171-3.

1. Concept paper:

Self-embedding of foreign bodies (SEFB) is a form of self-injury which involves the insertion of inanimate objects into soft tissues, under the skin or into muscle, to

deliberately hurt them or mutilate their bodies without intending to suicide (1).

This SEFB behavior was first discovered by radiologists (2). Though it is reported in scientific literature, it is not reported in forensic literature.

Foreign bodies are usually inserted through existing orifices. But, self-embedding by breaching of an epithelium is less common. Reasons for self-embedding may be border lying personality disorders, post-traumatic stress disorder, schizophrenia, sadistic

Corresponding author: Vidanapathirana M,
Department of Forensic Medicine, Faculty of Medical Sciences, University of Sri Jayewardenepura, Sri Lanka.
E-mail: mudithavidana@gmail.com

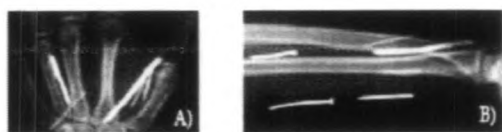


Fig. 1. Nails and needles found in limb.

behavior and many conditions (3). Self-embedding is a form of self-mutilation. Although it is a symptom of a larger underlying problem, it is often overlooked because it occurs in many diverse settings, is hidden or underreported, and is underdiagnosed in healthcare settings (4). It requires aggressive and timely interdisciplinary assessment and treatment (1).

In 1936, the child murderer Albert Fish was X-rayed and found 29 needles inserted into his groin (5). In 2008, in a study done in Canada, some teenagers were found to be using SEFB as an extreme form of self-injury, embedding sharp items deep into their flesh (4). In the year 2010, a housemaid returned from Saudi Arabia with 24 nails and needles in her limbs and face and in the X-rays, they were found to be placed parallel to the skin surface (Figure 1A). Soon after returning to Sri Lanka, she had not informed that she had been 'tortured' by her employer (6).

In the year 2013, another Sri Lankan housemaid from Middle East admitted to hospital with needles in her body. According to the victim, those needles were inserted by her master for sexual gratification. She was in depressed state but did not have any intention to obtain compensation.

On examination, there were no stigma of self-inflicted injuries and the needles were not found at inaccessible areas. X-rays showed needles in her limbs and face placed parallel to the skin surface (Figure 1B). The Psychiatrist confirmed that she did not have any major psychiatric disorders.

In a research done in Nigeria, found that the most frequently reported form of self-injury is cutting of the sub-dermal tissue and severity ranges from superficial cutting to deep disfigurement and the number of foreign bodies embedded per case ranged from 1-15 and the objects were metal,

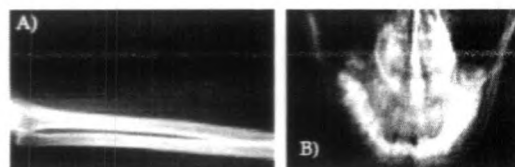


Fig. 2. X-rays of needles (shown by arrows) in limbs and face.

plastic, graphite, glass, wood, crayon, and stone (7). Ultrasound is used to identify nonradiopaque objects not detectable on x-ray (7).

The consequences of self-embedding can become significant. Wounds can become infected, and this is worsened when foreign objects are inserted deep into the tissue. Infection can extend to bone or muscle, and further, it can damage blood vessels, nerves, or tendons. An object can become emboli and stuck in a vital organ (8). These have to be assessed for compensation purposes, when an embedding is committed by a third party. Foreign body embedding by a third party is alleged in circumstances such as trafficking, child abuse, domestic violence, sexual abuse etc.

Intention of self-embedding is false allegation or compensation. The medicolegal issues would be, whether they were self-embedded or not.

Similar self-inflicted embedding are found in patients with Munchausen syndrome (MS) which is defined as a psychiatric factitious disorder where those affected seek sympathy or attention to themselves (3) and achieved by self-embedding of foreign bodies (9). Munchausen syndrome also can be classified as a subtype of somatoform disorders, as these two disorders share a lot of characteristics (10).

In somatoform disorder, there are persistent physical symptoms linked to psychological factors, without a demonstrable organic or physiological explanation (9) and may choose deliberate self-harm (11) expressed as self-embedding of foreign bodies.

In conclusion, 'The medico-legal significance of self-embedding of foreign objects' is a new concept. Multiple foreign objects, found parallel to body surface, at accessible sites, in accessible directions to push foreign bodies between the thumb and

index fingers favors self-embedding. To diagnose 'self-embedding of foreign bodies (SEFB)' for forensic purposes, the forensic physician has to exclude 'torture' by third party before ascertaining the concept of self-harm. It requires multidisciplinary assessments and interventions.

References

1. Bennett GH, Shiels WE 2nd, Young AS, Lofthouse N, Mihalov L. Self-embedding behavior: a new primary care challenge. *Pediatrics*. 2011;127(6):1386-91.
2. Young AS, Shiels WE 2nd, Murakami JW, Coley BD, Hogan MJ. Self-embedding behavior: radiologic management of self-inserted soft-tissue foreign bodies. *Radiology*. 2010;257(1):233-9.
3. American Psychiatric Association. *Diagnostic and Statistical Manual of Mental Disorders (5th ed.)*. American Psychiatric Publishing. 2013;645.
4. Pigg S. "Disturbing trend shows troubled teens pushing sharp items deep into their flesh". *The Daily Gleaner* (Brunswick Press). 2009. p. C5. (accessed on 31.01.2014)
5. Frasier DK. *Murder Cases of the Twentieth Century. Biographies and Bibliographies of 280 Convicted or Accused Killers*. 1996; McFarland & Company (Publisher). 1996.
6. Doctors extract nails stuck into Sri Lankan maid. <http://www.theguardian.com/world/2010/aug/27/sri-lanka-maid-saudi-arabia> (accessed on 12.01.2014)
7. Young AS, Shiels WE, Murakami JW, Coley BD, Hogan MJ. Self-embedding behavior: radiologic management of self-inserted soft-tissue foreign bodies. *Radiology*. 2010;257:233-239.
8. Mangnall J, Yurkovich E. A literature review of deliberate self-harm. *Perspect Psychiatr Care*. 2008;44:175-84.
9. Falagas ME, Christopoulou M, Rosmarakis ES, Vlastou C. Munchausen's syndrome presenting as severe panniculitis. *Int J Clin Pract*. 2004;58(7):720-2.
10. Reich E, Kajosh H, Verbanck P, Kornreich C. Munchausen's syndrome: a factitious disorder? A case report. *Rev Med Brux*. 2013 Nov-Dec;34(6):485-90.
11. Dhossche D, Van der Steen F, Ferdinand R. Somatoform disorders in children and adolescents: a comparison with other internalizing disorders. *Ann Clin Psychiatry*. 2002;14(1):23-31.